


Case Study

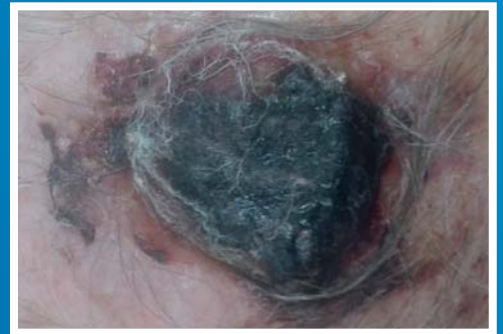Single application of dCELL[®] Human Dermis
Thick graft for scalp malignancy^[1]

- 72 year old male
- Squamous Cell Carcinoma of the Scalp
- Thick graft 4x4cm applied

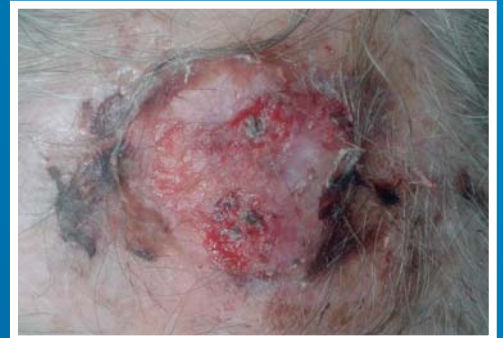


dCELL[®] Human Dermis

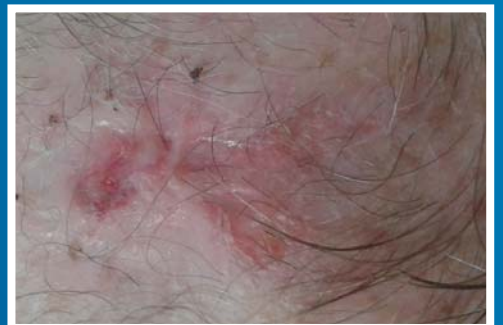Day 21



Day 22



Week 6





Reference

- 1 Mr J Elliott, Consultant Oral and Maxillofacial Surgeon, Cumberland Infirmary Hospital, Carlisle (personal communication, July 2015)