


# Case Study 2

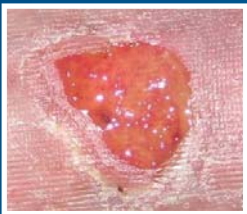Single application of dCELL<sup>®</sup> Human Dermis for treatment resistant venous ulcer<sup>[1]</sup>

- 72 year old female
- Venous ulcer, left tibial crest
- 15 months duration

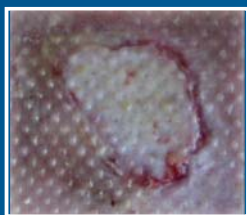

**dCELL<sup>®</sup> Human Dermis**

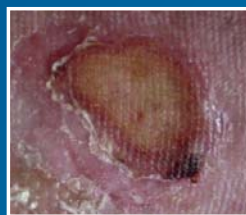Day 0



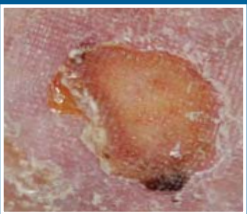
Week 1



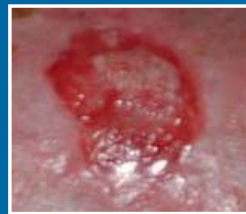Week 2



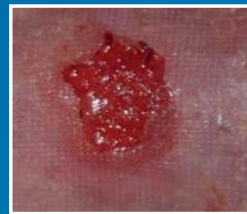Week 3



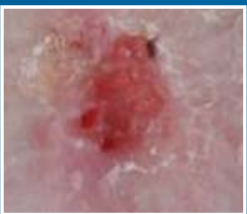Week 4.5



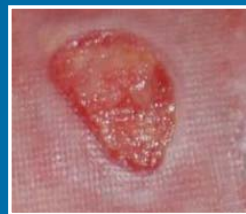Week 6



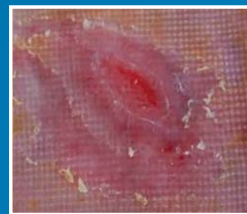
Week 8



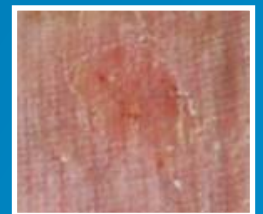3 Months

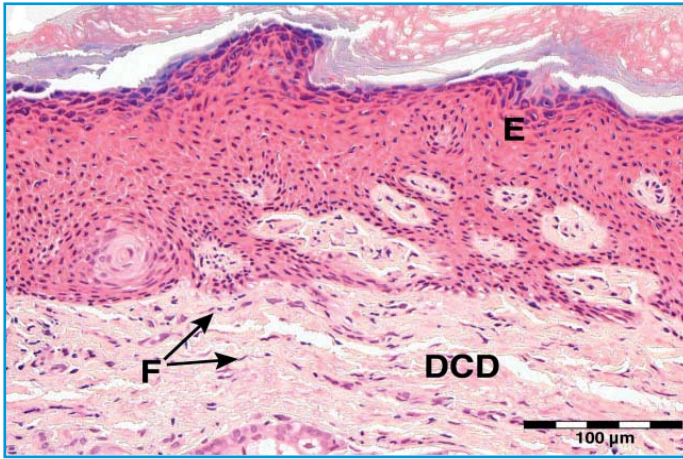


4 Months



4.5 Months



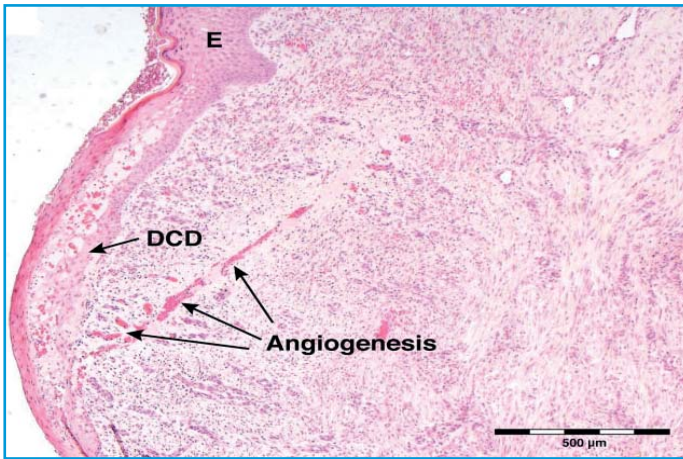


Punch biopsy taken 6 weeks after DCD graft application.

Recolonisation of DCD with fibroblasts.

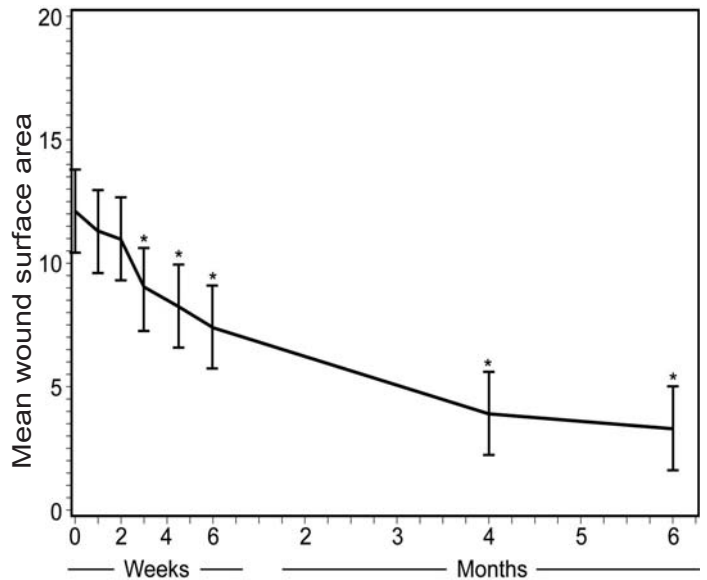
Regeneration of the epidermis.

Formation of new blood vessels.



(E) Epithelium  
 (F) Fibroblasts  
 (DCD) dCELL<sup>®</sup> Human Dermis

Plot of mean changes in surface area from baseline in 20 donors, with 95% confidence intervals.  
 \* $p \leq 0.05$  [1]



## Reference

1 Single-stage application of a novel decellularized dermis for treatment-resistant lower limb ulcers: Positive outcomes assessed by SIAscopy, laser perfusion, and 3D imaging, with sequential timed histological analysis. Nicholas S. Greaves, MBChB; Brian Benatar, FRCpath; Mohamed Baguneid, MD; Ardeshir Bayat, MBBS, PhD. *Wound Repair Regen.* 2013 Oct; 21(6): 813–822.